

Endoscopic Coronary Artery Bypass Graft (ECABG) Procedure with Robotic Assistance



Dr. Tabaie

(#1999-0552 ... September 7, 1999)

Harold A. Tabaie, DO, PhD, Jeffrey A. Reinbolt, BS, W. Peter Graper, MD, Thomas F. Kelly, MD, Michael A. Connor, RN

The Center for Advanced Surgery, Sarasota Memorial Healthcare System, Sarasota, Florida

ABSTRACT

Background: Technical details of the robotically assisted endoscopic coronary artery bypass graft (ECABG) procedure on the cadaver model are reported. Moreover, this study will provide essential techniques, steps, and procedural development concepts necessary to introduce the ZEUS™ Robotic Surgical System (Computer Motion, Inc., Goleta, CA) into the human operating room.

Methods: Between August 1998 and March 1999, an ECABG procedure was performed on 10 cadaver torsos. The cadaver torso was placed in the left anterior oblique (LAO) position. The left and right internal mammary arteries (IMA) were taken down endoscopically. The ends of the IMA's were intracorporeally prepared. An upper partial sternotomy was demonstrated for perfusion cannulation and proximal anastomoses for multiple vessel revascularization. An arteriotomy was created with an endoscopic scalpel. The IMA was anastomosed to a chosen coronary using robotic assistance. The patency was verified by probing and injecting of methylene blue.

Results: Templates were developed to determine the placement of the robotic arms. Port templates were developed to both harvest the IMA's and perform the desired anastomoses. The following vessels were accessed through the developed port templates and retraction of the heart: left anterior descending (LAD), right coronary artery (RCA), diagonal (D1), obtuse marginal (OM1 and OM2), and posterior descending artery (PDA).

Submitted September 3, 1999; accepted September 7, 1999.

Address correspondence and reprint requests to: Harold A. Tabaie, D.O., Ph.D., Bradenton Cardiac Surgeons, Riverside Medical Center, Suite 2600, 300 Riverside Drive East, Bradenton, FL 34208, Phone: (941) 746-0221, Fax: (941) 750-0473

Conclusions: The use of robotic assistance during an ECABG procedure on a cadaver model is feasible. This study is a necessary and useful progression from the use of robotics in the animal lab to the use of robotics in the human operating room.

INTRODUCTION

In part, the impressive achievements associated with conventional CABG surgery are largely attributable to an excellent surgical "platform" — full sternotomy and total exposure of the heart, cardiopulmonary bypass support, myocardial protection, and a bloodless, motionless surgical field that combine to facilitate precise anastomotic suturing. Both port-access and minimally invasive direct coronary artery bypass (MIDCAB) procedures present far higher technical challenges, which have been shown to occasionally surpass the skills of even the most expert surgeons [Amunson 1997].

Of all the technical challenges accompanying coronary artery bypass surgery, the most important element lies in the construction and performance of a perfect anastomosis. Moreover, revascularization success ultimately rests on a technically superior graft that supplies adequate blood flow to the ischemic area of the heart for an extended period of time [Amunson 1997].

Cardiac surgery remains the largest surgical discipline that still employs a highly invasive approach. This is primarily due to the difficulty encountered in performing the precise and highly dexterous motions required to endoscopically suture the tiny coronary vessels on the heart with hand-held instrument [Amunson 1997]. Endoscopically sutured anastomoses have not been possible because of the length and imprecision of standard endoscopic instrumentation [Mack 1997, Stephenson 1998]. Prolonged intracorporeal microsuturing procedures provide a significant challenge for surgeons. Although endoscopic

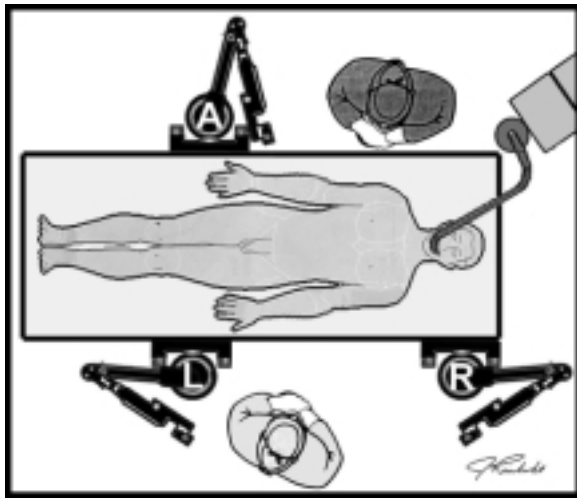


Figure 1. Overhead diagram of the robotic arm placement and orientation prior to surgery. "A, L, & R" indicate AESOP® (endoscope arm), Left arm, & Right arm, respectively.

magnification enhances visual perception, the optically magnified hand tremor forces the surgeon to slow down in order to compensate for diminished dexterity. Longer operative time leads to surgeon fatigue, which further amplifies the hand tremor, thus completing a malicious cycle [Soper 1992, Cushieri 1995, Falcone 1999].

Recently robotics has been developed to assist in endoscopic suturing [Borst 1997, Mack 1997, Stephenson 1998]. Robotic assistance for endoscopic surgery has dramatically improved in the last five years [Gagner 1994, Kavoussi 1994, Sackier 1994, Begin 1995, Kavoussi 1995, Moore 1996, Falcone 1999]. The most recent advances in robotic technology have made it possible to simultaneously manipulate the endoscope and various endoscopic instruments, enabling full robotic assistance to perform several aspects of the surgical procedure [Falcone 1999].

With computer dampening of the surgeon's hand tremor and scaling of the surgeon's movements, robotics may provide the precision necessary to perform endoscopic coronary anastomoses [Mack 1997]. We believe that robotic assistance will enable fully endoscopic CABG surgery. As a result, these new minimally invasive surgery procedures will provide significant benefits for patients such as: decreased operative trauma and pain, shorter hospital stays and convalescent periods, and lessened cosmetic concerns. Furthermore, an increase in minimally invasive procedures will result in lower overall healthcare cost [Amunson 1997].

Before robotics enter the cardiac marketplace, or the cardiac operating room for that matter, several procedural, equipment, and choreographic questions must be answered. The results of this study will form a solid foundation in answering such questions. The study will provide a convincing statement to cardiac surgeons, the operating room team, and their patients concerning the feasibility, reproducibility, and desirability of a multiple vessel ECABG procedure on a human model using robotic assistance.

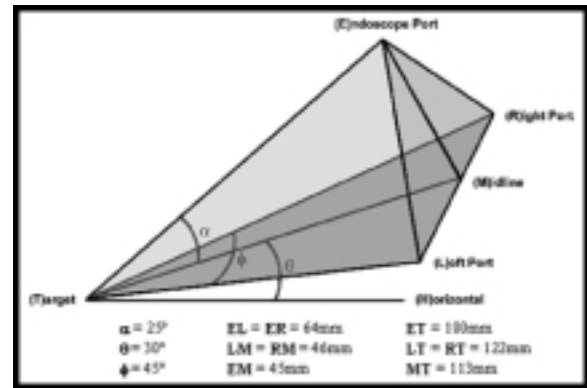


Figure 2. Diagram of the ideal instrument and endoscope port setup in the dry laboratory setting.

MATERIALS AND METHODS

Suitability of a donor for cadaver tissue donation is initially determined by a review of the donor's medical and social history. Tissues are obtained from donors who are free from infections, malignant diseases, and diseases of unknown etiology that may involve a transmissible agent. Extensive bacteriological studies of the blood and tissues are performed. In addition, donors are screened using standard serological tests including, but not limited to: HIV-1-Ag, HIV-1/2-Ab, HTLV-1Ab, HBs-Ag, HBc-Ab, HCV-AB, STS, and HIV DNA by PCR testing. Cadaver torsos were exclusively purchased from the Anatomic Gift Foundation, Phoenix, AZ.

Cadaver tissue remained in the freezer (-120 C) prior to use, as the tissue was fresh frozen and had not been embalmed or preserved. Two days prior to the scheduled lab session, the cadaver tissue was removed from the freezer and placed in an alcove to thaw at room temperature. The cadaver was placed on the table in the left anterior oblique (LAO) position. This was maintained through the use of a 34.5" x 28" Vac Pac, Size 35 (Olympic Medical, Seattle, WA). The left arm was secured above the head to allow access to the mid-axillary line of the left chest for the endoscopic IMA takedown. External landmarks were identified and indicated with a marking pen.

The equipment was placed in the room according to the standard open-heart room setup at this institution. Adequate space remained for equipment which was not necessary for this lab but would typically be in use in the OR (e.g., perfusion, anesthesia, etc.). The robotic arms were attached to the table rails and positioned relative to the patient. The robotic arms were connected to the surgeon console and the system was powered on. The robotic arms were then rotated away from the operative area to allow the surgeon access to the patient's left chest (see Figure 1 ©).

A 5 mm port was inserted in the fourth ICS at the mid-axillary line. Insufflation, Electronic Endoflator #26430520 (Karl Storz, Tuttlingen, Germany), was used to drop the lung and provide more working space. A 5mm zero degree Hopkins II #26006AA endoscope (Karl Storz, Tuttlingen,

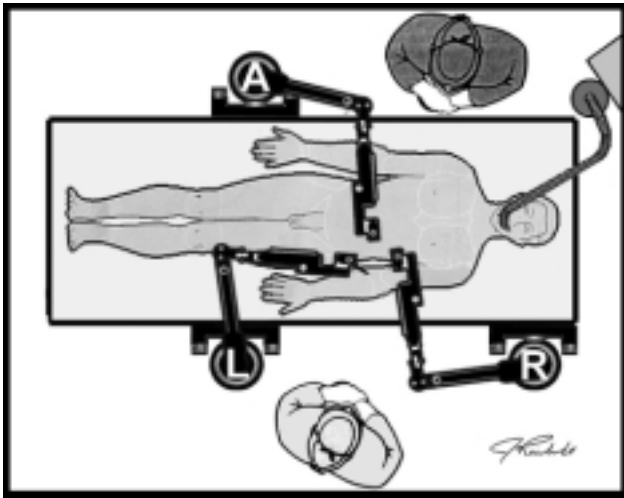


Figure 3. Overhead diagram of the robotic arm placement and orientation during the robotically assisted anastomosis. "A, L, & R" indicate AESOP® (endoscope arm), Left arm, & Right arm, respectively.

Germany) was placed into the port. Light was provided by a Xenon 300 #20133020 (Karl Storz, Tuttlingen, Germany) light source set at 50%. The video image was produced by a Tricam SL NTSC #20222120 (Karl Storz, Tuttlingen, Germany) 3 chip CCD camera.

Two additional 5 mm ports were inserted to begin the IMA takedown. The ports' placements were chosen to have two of the IMA ports used during the left anterior descending (LAD) anastomosis. These ports also approach the ideal port setup developed in previous dry lab experiments (see Figure 2 ☉).

The IMA was taken down with the following, in separate cases: hand-held endoscopic cautery, Mayfield Suction/Cautery Electrode™ (Snowden Pencer, Fall River, MA); hand-held endoscopic Harmonic Scalpel Blade (Ethicon Endosurgery, Cincinnati, OH); robotic positioned endoscopic Harmonic Scalpel Blade; robotic positioned endoscopic cautery, ZEUS™ hook cautery (Computer Motion, Goleta, CA). The IMA end was prepared intracorporeally with the "Koh" laparoscopic instrument set (Karl Storz, Tuttlinger, Germany). The pericardium was opened using these hand-held endoscopic instruments as well.

A minimally invasive cannulation and perfusion technique was demonstrated using a 6 cm upper partial sternotomy. Two alternate techniques were exercised using a para-sternal incision or a supra-sternal notch incision for cross-clamp access in combination with groin cannulation.

A fourth 5 mm port was placed inferior to the previous three. The lower IMA takedown instrument was shifted to this newly positioned port. The endoscope was shifted to the initial position of the lower IMA takedown instrument. The upper IMA takedown instrument was shifted to the initial position of the endoscope. The port initially used for the upper IMA takedown instrument became the assistant's instrument port. The chosen coronary was dissected using hand-held endoscopic instruments. The arte-



Figure 4. Digital images of the LIMA takedown with robotic assistance. The top and bottom images depict viewing the table from its foot and left, respectively.

riotomy was created using an endoscopic #11 blade. When necessary, the arteriotomy was extended with the "Koh" scissors. The robotic arms were brought into place to perform the anastomosis (see Figure 3 ☉).

The anastomosis was constructed with double-armed 7-0 Goretex (W.L. Gore, Flagstaff, AZ). The assistant provided counter traction on the tissue as the surgeon passed each needle through the IMA heel. The surgeon continued down the right side of the arteriotomy and around the toe. The surgeon finished with the opposite needle down the left side of the arteriotomy. Multiple square knots were tied at approximately the 5 o'clock position on the anastomosis, where the two suture ends met. Following the procedure the anastomosis was probed and injected with methylene blue to test for patency.

RESULTS

The left internal mammary artery (LIMA) was endoscopically harvested in each of the ten cadavers. Hand-held instruments were used to takedown the first nine LIMAs and ZEUS™ (Computer Motion, Goleta, CA) was used to takedown the tenth and final LIMA (Figure 4 ☉). The cautery provided a familiar feel during the takedown; however, it was very necessary to evacuate the smoke produced by the cautery. In turn, the smoke evacuation created a vacuum that counteracted the insufflation. The har-

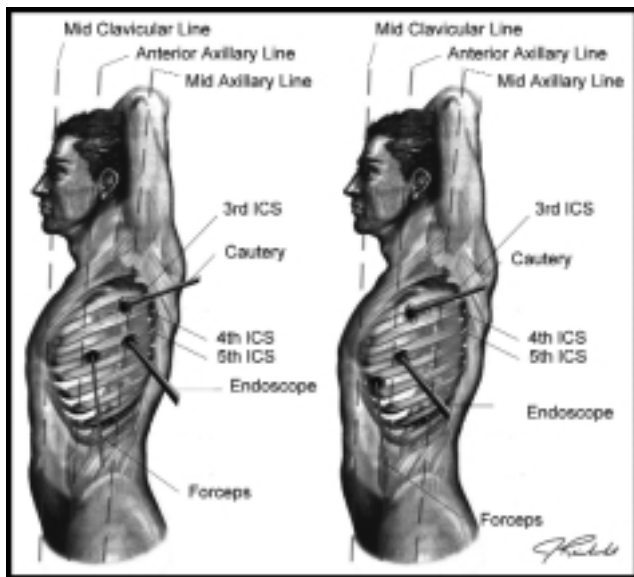


Figure 5. Port placement diagrams for the endoscopic harvest of the Left Internal Mammary Artery. The left image depicts the port strategy developed for smaller patients and the right image depicts the port strategy for larger patients.

monic scalpel appeared slower compared to cautery, but there was no need to evacuate smoke since it was not produced (see Figure 4 ☉). Two variations of a common port strategy were developed (see Figure 5 ☉).

These particular port strategies were developed to allow two of the LIMA takedown ports to also be used for the ZEUS™ (Computer Motion, Goleta, CA) anastomosis, minimizing the total number of ports necessary for both portions of the procedure. (see Figure 6 ☉).

The LAD and diagonal (D1) arteries were accessed and anastomosed with the above port setup (without tissue retractors). The obtuse marginal (OM1 and OM2) were accessed through the above port setup with the assistant providing retraction and slight rotation of the heart. The posterior descending artery (PDA) and right coronary artery (RCA) were accessed through the above port setup with the assistant retracting the heart muscle through a port placed in the fourth intercostal space at the mid-clavicular line. It proved to be helpful, but not necessary, to have the assistant's second instrument enter through a port inferior to the ZEUS™ (Computer Motion, Goleta, CA) right instrument on the mid axillary line.

The robotic arms were found to be versatile in their placement on the table rails. The robotic arm placement strategies (see Figure 7 ☉) were developed to coincide with the above port placement strategies (see Figure 6 ☉).

In order for the endoscope holder, AESOP® (Computer Motion, Goleta, CA), to access the entire length of the IMA, the robotic arm must be placed directly across the table from the endoscope port. The degree of "elbow bend," or amount the robotic arm bends towards the floor, is proportional to the patient's size and degree of rotation. For example, if the patient is extremely large, the robotic arm will need more bend to reach over and

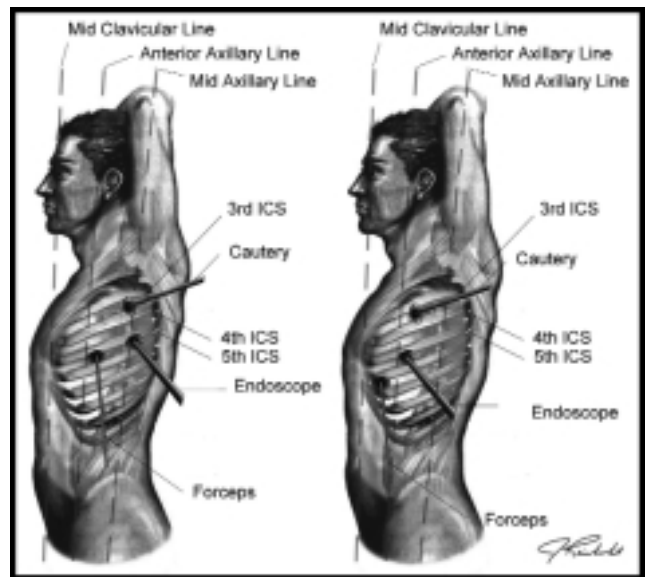


Figure 6. Port placement diagrams for the endoscopic robotically assisted anastomoses.

around the patient's chest to access the endoscope port. However, if a large patient is rotated approximately 30 degrees, then the robotic arm will need less bend to access the same endoscope port.

The upper and lower arms may be placed as shown above (Figure 7 ☉). However, these configurations only allow access to the anastomoses and do not provide adequate access to the LIMA takedown. More specifically, access is not possible to the proximal and distal ends of the IMA. Likewise, there are several robotic arm arrangements that provide access to the LIMA takedown and not the anastomoses. It was discovered that an ideal robotic arm placement strategy was necessary to permit access to both the entire LIMA takedown and the anastomoses (Figure 8 ☉).

This arrangement allows both portions of the procedure to be performed with robotic assistance. Moreover, the robotic arms will not need to be repositioned on the table rails during the procedure, which may compromise the sterile field.

DISCUSSION

Endoscopic coronary artery bypass grafting is a long, exhaustive, and difficult procedure. Fifteen years ago, general surgeons were describing the laparoscopic cholecystectomy procedure in this same way. Initial attempts at a totally endoscopic approach to cardiac surgery have been abandoned in favor of a mini-thoracotomy [Stephenson 1998, Schwartz 1997, Schwartz 1999]. The final goal of a fully endoscopic coronary artery bypass has not yet been realized and this procedure must wait until cardiac instrumentation technology advances and overcomes the technical challenges and limitations of today [Stephenson 1998].

Medical robotics have been manufactured and in use for some time. Only recently, medical robotics has been

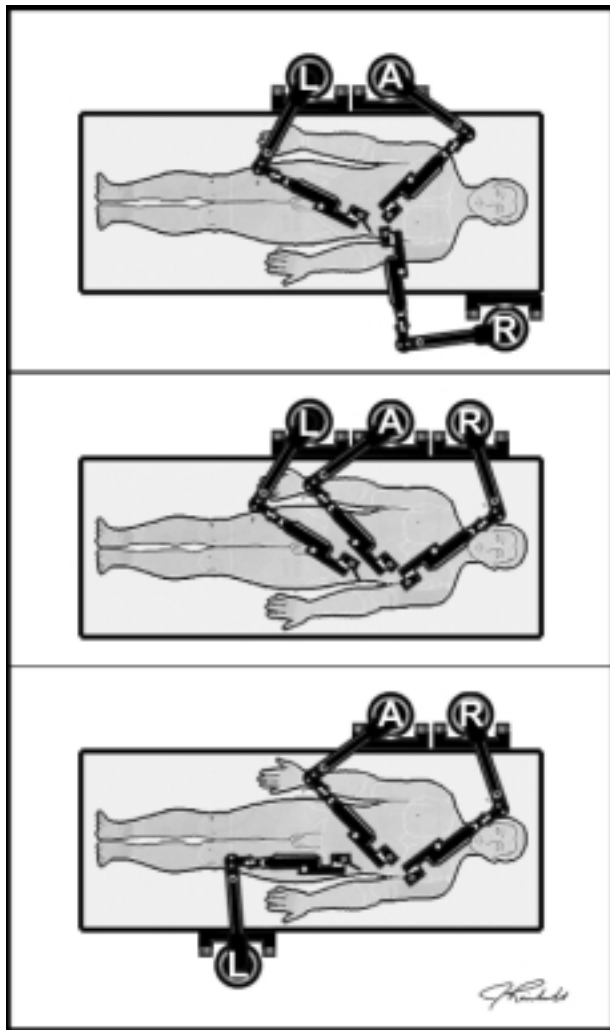


Figure 7. Robotic arm placement diagrams for the ZEUS anastomoses. "A, L, & R" indicate AESOP® (endoscope arm), Left arm, & Right arm, respectively.

introduced to the cardiac community. The robotic system does not replace a surgeon; however, it does significantly enhance a surgeon's skills and dexterity. The robotic system provides substantial assistance in performing extensive endoscopic procedures, such as: 1) natural hand tremor is electronically eliminated, 2) the surgeon's instrument movements are selectively scaled down, and 3) visualization of the magnified surgical field is controlled by robotic assistance. Such benefits, in addition to comfortably sitting in an ergonomically designed chair, result in reduced fatigue, precise surgical movements, added stability, and surgeon comfort.

The current study demonstrates that an endoscopic coronary artery bypass grafting procedure with robotic assistance is technically feasible. Proper port placement setup plays an essential role in extensive endoscopic suturing procedures [Cushieri 1995]. Moreover, the robotic arm placement setup is paramount to reducing the degree of difficulty and ensuring the success of the procedure. Fur-

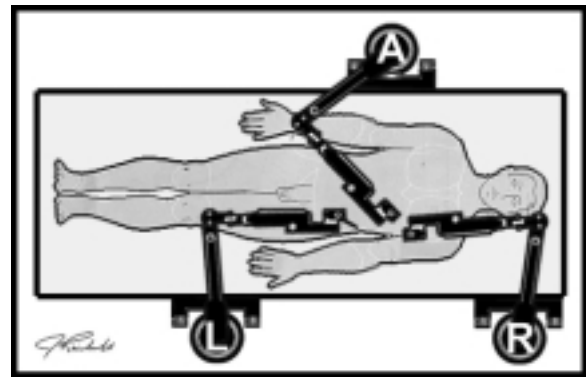


Figure 8. Robotic arm placement diagram for both the robotically assisted IMA takedown and the robotically assisted anastomosis. "A, L, & R" indicate AESOP® (endoscope arm), Left arm, & Right arm, respectively.

ther studies are necessary, including human clinical trials reviewed by the Food and Drug Administration, to determine the role robotic assistance will have in future cardiac procedures. As a precursor to an FDA approved study, the first clinical series of cardiac patients was initiated on September 16, 1998, at University Hospital, Grosshadern, Munich, Germany (16). The current study provides a foundation that robotic instrumentation may enable completely endoscopic coronary artery bypass procedures; furthermore, this study provides technical details and procedural development concepts necessary to introduce robotics into the human operating room.

REFERENCES

1. Amunson AL, Baker CS, et al. "MIDCAB Technique." *Cardiac Surg Renaissance* 99:101, 1997.
2. Begin E, Gagner M, Hurteau R, de Santis S, PompA. A robotic camera for laparoscopic surgery: conception and experimental results. *Surg Laparosc Endosc*, 5:6-11, 1995.
3. Borst C, Santamore WP, Smedira NG, Bredee JJ. Minimally invasive coronary artery bypass grafting: on the beating heart and via limited access. *Ann Thorac Surg* 63:S1-5, 1997.
4. Cushieri A, Szabo Z. *Tissue approximation in endoscopic surgery*. (Oxford: Isis Medical Media 42-139, 1995).
5. Falcone T, Goldberg J, Garcia-Ruiz A, Margossian H, Stevens L. Full robotic assistance for laparoscopic tubal anastomosis: a case report. *Journal of Laparoendoscopic & Advanced Surgical Techniques* 9(1):107-13, 1999.
6. Gagner M, Begin E, Hurteau R, Pomp A. Robotic interactive laparoscopic cholecystectomy. *Lancet* 343:596-7, 1994.
7. Kavoussi LR, Moore RG, Adams JB, Partin AW. Comparison of robotic vs. human laparoscopic camera control. *J Urol* 6:2134-6, 1995.
8. Kavoussi LR, Moore RG, Partin AW, Bender JS, Zenilman ME, Satava RM. Telerobotic assisted laparoscopic surgery: initial laboratory and clinical experience. *Urology* 44:15-19, 1994.
9. Mack MJ, Acuff TE, Casimir-Ahn H, Lonn UJ, Jansen EWL. Video-assisted coronary artery bypass grafting on the beating

- heart. *Ann Thorac Surg* 63:S100–3, 1997.
10. Moore RG, Adams JB, Partin AW, Docimo SG, Kavoussi LR. Telementoring of laparoscopic procedures. *Surg Endosc* 10:107–10, 1996.
 11. Reichenspurner H, Damiano RJ, Mack M, Boehm D, Gulbins H, Detter C, Meiser BM, Ellgass R, Reichart B. Use of the voice-controlled and computer-assisted surgical system Zeus™ for endoscopic coronary artery bypass grafting. *J Thorac Cardiovasc Surg* 118:11–16, 1999.
 12. Sackier JM, Wang Y. Robotically assisted laparoscopic surgery. *Surg Endosc* 8:63–66, 1994.
 12. Schwartz DS, Ribakove GH, Grossi EA, et al. Single and multivessel Port-Access coronary artery bypass grafting with cardioplegic arrest: technique and reproducibility. *J Thorac Cardiovasc Surg* 114:46–52, 1997.
 13. Schwartz DS, Ribakove GH, Grossi EA, et al. Minimally invasive mitral valve replacement: Port-Access technique, feasibility, and myocardial function preservation. *J Thorac Cardiovasc Surg* 118:11–16, 1999.
 14. Soper NJ, Hunter JG. Suturing and knot tying in laparoscopy. *Surg Clin North Am* 72:1139–52, 1992.
 15. Stephenson ER Jr., Sankhokar S, Ducko C, Daminao RJ Jr. Robotically Assisted Microsurgery for Endoscopic Coronary Artery Bypass Grafting. *Ann Thorac Surg* 66(3):1064–7, 1998.

REVIEW AND COMMENTARY

1. Editorial Board Member SG14 writes:

- a) This paper evaluates port positioning in terms of a combination of IMA harvesting and robot-assisted coronary anastomosis using a particular device. A 6 cm upper partial sternotomy is used for cannulation for institution of CPB. There are already reports about performing the whole procedure (cannulation and multiple bypass surgery) over a 7 to 9 cm chest incision without upper sternotomy.
- b) What about LIMA harvesting, anastomosis time and procedure time?
- c) How many anastomoses were performed per case?
- d) Which vessels were accessed in each case?
- e) When performing OM1 and OM2 anastomoses, were sequential bypass grafts performed?

Authors' Response by Harold A. Tabaie, DO, PhD:

- a) This paper evaluates positioning of the robotic arms (relative to the patient) with this the particular telemanipulation system. The major objectives of this study were to 1) develop a template for the placement of the robotic arms so it will be unnecessary to reposition the arms throughout a multiple vessel procedure, and 2) develop a template for the placement of a minimal number of ports to access the LIMA and multiple coronary vessels. The upper partial sternotomy incision allows access for both the cannulas and the cross clamp. The size of the incision may be significantly reduced by cannulating the groin and using the partial sternotomy for the cross clamp only. To date, a minithoracotomy has only been used during robotically assisted clinical

cases instituting Heartport's Intra-Aortic Balloon.

- b) As for harvesting and anastomotic times, these were not reported; due to the fact that times obtained during cadaveric work cannot be compared to times recorded in a clinical setting, for obvious reasons. With this being recognized, the following times were recorded:

Mean LIMA harvesting time equals 38 ± 9.06 minutes.
Mean anastomosis time equals 34.13 ± 6.83 minutes.
Procedure time was not recorded.

- c) At the least, the LAD and D1 were anastomosed in each of the ten cases. Time and on-call emergencies permitting, additional distal anastomoses were performed on the RCA and OM1 and OM2. At the most, four anastomoses were performed during one case. The mean number of anastomoses per case equaled 3.00 ± 0.94 .
- d) In this context "access" will be defined as: clear visual identification and orientation of the target vessel, with appropriate orientation of upper and lower instruments (relative to the vessel) to enable the anastomosis to be performed. With this definition, the LAD and D1 were accessed in each of the ten cases. The OM1 and OM2 was accessed in six cases. The RCA and posterior descending artery were accessed in four cases.
- e) Several of the authors have discussed the plausibility of performing sequential IMA grafts with robotic assistance. However, to date the demonstration of performing these anastomoses with robotic assistance has not been conducted.

2. Editorial Board Member JZ39 writes:

I also did not understand how the right mammary was procured. An illustration of this would be helpful.

Authors' Response by Harold A. Tabaie, DO, PhD:

The procurement of the right IMA was not considered to be a portion of a clinical case; however, the harvesting of the right IMA was used for additional practice of endoscopic skills training and the vessel itself was used as an additional conduit to perform multiple distal anastomoses (in addition to the LIMA, unfortunately saphenous vein and/or radial artery were not available).

Invited Commentary from Hermann Reichenspurner, MD, PhD, Department of Cardiac Surgery, University Hospital Munich-Grosshadern, D-81366 Munich, Germany:

The final goal of minimally invasive coronary artery surgery would obviously be a fully endoscopic coronary artery bypass grafting procedure (ECABG). The article by Tabaie et al. describes the use of the surgical robotic system ZEUS™ for performing ECABG in human torsos. This manuscript describes the importance of correct port placement for the endoscope as well as for the instrument arms which is absolutely essential before performing any endoscopic procedure. The left internal mammary artery (LIMA) was harvested endoscopically using hand-held instruments. The pericardium was opened manually. For cannulation the authors describe a 6 cm upper partial sternotomy. The arte-

riotomy was also done manually using an endoscopic blade. The anastomosis of the LIMA to LAD was done using the ZEUS™ instrument arms through the instrument ports.

There is an obvious need to include computer enhanced instrumentation systems, such as the described surgical robotic system ZEUS™, to perform microsurgical procedures, such as coronary artery bypass grafting, fully endoscopically. There have been several attempts in manual endoscopic coronary artery anastomoses, but most of them failed or would otherwise be limited to a few "virtuosos" in cardiac surgery. One of the important features of surgical robotic systems are the improved ergonomics of the surgeon who sits at a console and is able to work out of a fully comfortable position. By a certain feature called "indexing", the surgeon is able to freeze the motion of the so-called slave-instruments at the patient, while he repositions the master-instruments at the console in a neutral position. In addition to this feature, such a computer enhanced system allows 10 degrees of scaling (referring to the ratio of movements of the master-instrument related to those of the slave-instrument). Thus, complex microsurgical movements can be done with high precision.

Currently two surgical robotic systems have been used experimentally and clinically. The da Vinci™ system (Intuitive Surgical Inc., Mountain View, CA) was used clinically for the first time in May of 1998 for valvular surgery and coronary artery surgery [Carpentier 1998, Mohr 1998]. The system ZEUS™ (Computer Motion Inc., Goleta, CA) was used experimentally first at Hershey Medical Center [Stephenson 1998]. The latter system was used clinically for the first time in September 1998 at the University of Munich, Germany [Reichenspurner 1999]. Thus, both surgical systems have already been used in a clinical setting for endoscopic coronary artery bypass anastomoses. Advantages of the da Vinci™ system are incorporated three-dimensional visualization and inclusion of a robotic wrist at the end of the instruments providing articulated motion with a full 7 degrees of freedom in motion inside the chest cavity. This feature is most advantageous in performing the LIMA harvests and for complex microsurgery. The instrument arms however measure 11 mm in diameter and the whole system is still relatively big and needs to be placed on the floor next to the patient. The system ZEUS™ (which is also described in the reviewed article) consists of three interactive robotic arms which are mounted onto the operating table. The instrument diameter is only 3.9 mm, but the current models lack an included articulated wrist thus allowing only 4 to 5 degrees of freedom inside the chest. This has proved to be completely sufficient in performing coronary artery anastomoses with similar anastomotic times achieved with both systems [Carpentier 1998, Mohr 1998, Reichenspurner 1999]. The absence of an internal wristed joint with Zeus™ might be, however, a limiting factor in performing more complex surgery, such as valvular reconstruction.

Next to correct port placement, another critical issue is two-dimensional versus three-dimensional visualization. Two-dimensional visualization, which has been used in the reviewed article, currently allows for better resolution

on monitor-based displays. There is however a significant lack in depth perception and a significantly longer learning curve for cardiac surgeons who do not go through a full endoscopic surgical training. The ZEUS™ system can, however, also be used in combination with independently developed three-dimensional visualization systems such as that supplied by VISTA™ (Vista Cardiothoracic Systems Inc., Westborough, MA).

Another important issue is the use of a cardiopulmonary bypass system for endoscopic coronary artery surgery. The method of using a partial sternotomy to allow cardiopulmonary bypass suggested in the experiments by Tabaie et. al. does not seem to be justified due to the availability of endovascular cardiopulmonary bypass systems. A specific Endo-CPB-System™ (Heartport Inc., Redwood City, CA) has been used by all cited authors to perform endoscopic on-pump coronary artery surgery on the arrested heart [Carpentier 1998, Mohr 1998, Reichenspurner 1999]. The ultimate goal however, would be to perform endoscopic coronary artery surgery without any cardiopulmonary bypass system, like the MIDCAB or OPCAB procedures. Critical issues for this goal are space inside the chest cavity and the necessary development of endoscopic coronary artery stabilizers. The first series on endoscopic off-pump coronary anastomoses has been published recently [Reichenspurner 1999]. So far, only the ZEUS™ system has been used for off-pump coronary artery surgery probably due to the small size of the end-instruments. A second series of off-pump endoscopic coronary artery surgery using the ZEUS™ has been started at the University of London, Ontario [Boyd 1999].

The answer to the question whether endoscopic coronary artery surgery using robotic systems is already a fully developed procedure would be definitely no. At all current centers these procedures still are in development and need major and minor modifications of the surgical systems as well as the strategy of those surgeries. Currently, operation times and times required for the coronary artery anastomoses are still significantly longer compared to regular coronary artery surgery. The other open question would be whether only single-vessel disease can be treated endoscopically or, ultimately, also multi-vessel disease. The current results reported by Tabaie et al., however, definitely justify further research and development with the ultimate goal of fully endoscopic off-pump computer-assisted multivessel coronary artery surgery.

REFERENCES

1. Carpentier A, Loulmet D, Aupeple B, Keiffer J, Tournay D, Fiemeyer A, et al. Computer-assisted open heart surgery: first case operated on with success. *C R Acad Sci III* 321:437-42, 1998.
2. Mohr FW, Falk V, Diegeler A, Autschbach R: Computer enhanced coronary artery bypass surgery. *J Thorac Cardiovasc Surg* 117:1212-5, 1998.
3. Stephenson ER, Sankholkar S, Ducko CT, Damiano RJ. Robotically-assisted microsurgery for endoscopic coronary artery

- bypass grafting. *Ann Thorac Surg* 66:1064–7, 1998.
4. Reichenspurner H, Damiano R, Mack M, Boehm D, Gulbins H, Detter C, et al. Use of the voice-controlled and computer-assisted surgical system ZEUS for endoscopic coronary artery bypass grafting. *J Thorac Cardiovasc Surg* 118:11–6, 1999.
 5. Reichenspurner H, Boehm D, Gulbins H, Damiano R, Mack M, Reichart B: Robotically assisted endoscopic coronary artery bypass procedures without cardiopulmonary bypass. *J Thorac Cardiovasc Surg*, in press, 1999.
 6. Boyd D, Menkis A: personal communication, 1999.